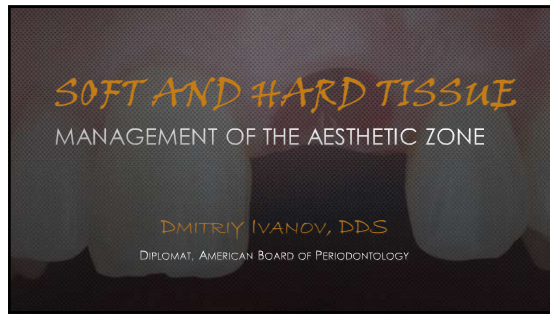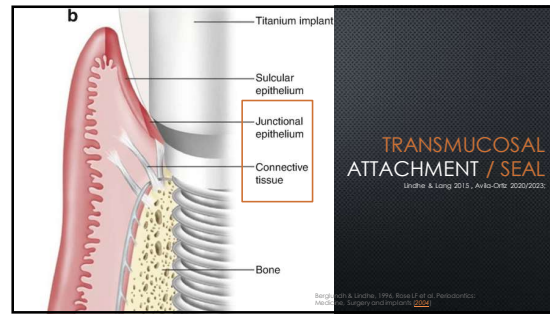
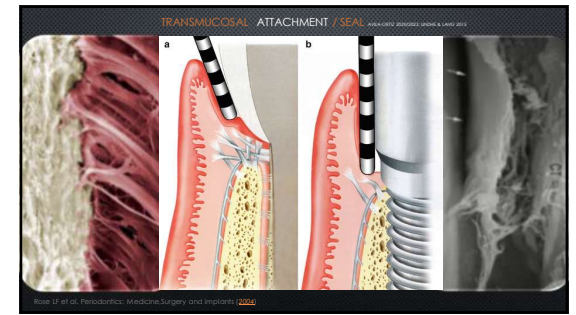


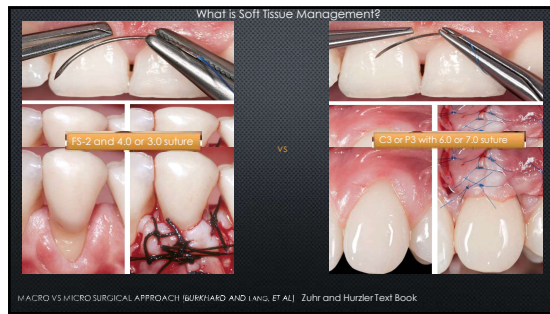
1



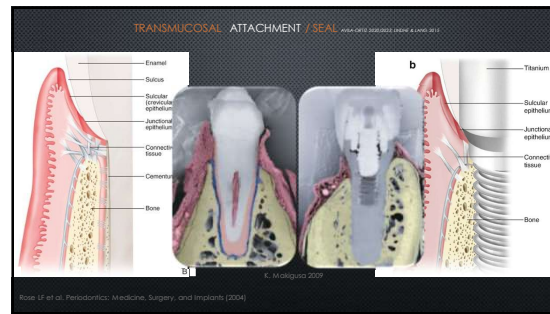
24



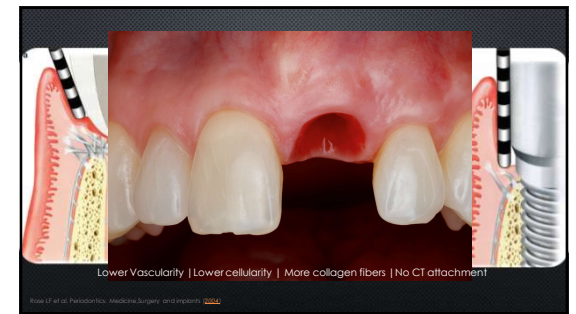27



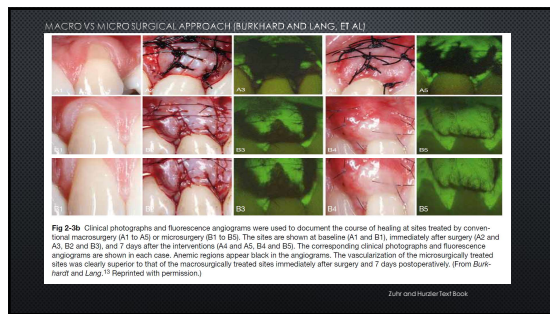
17



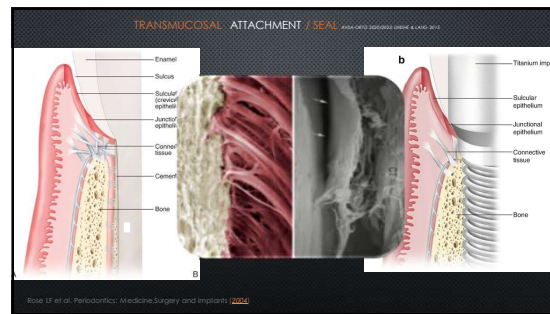
25



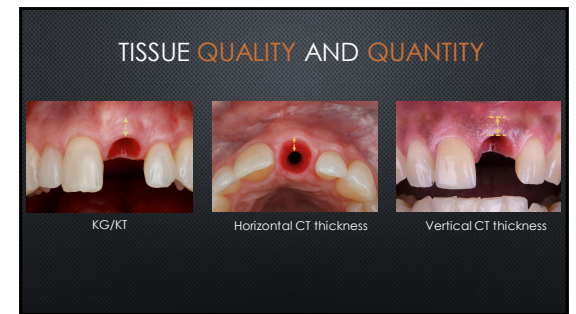28



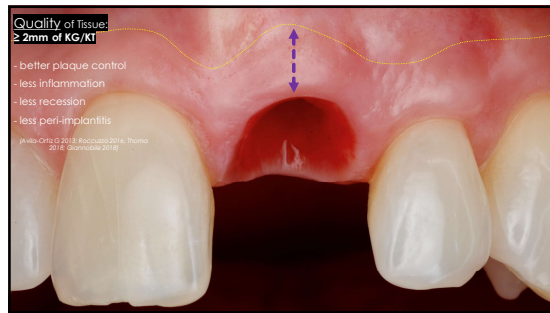
18



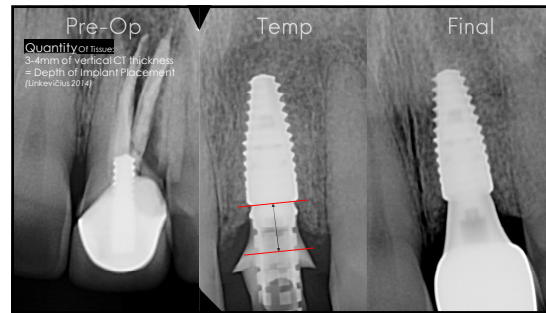
26



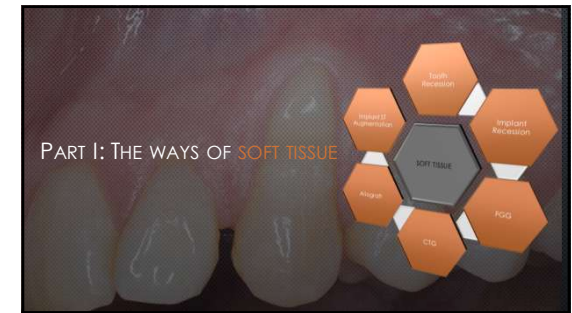29



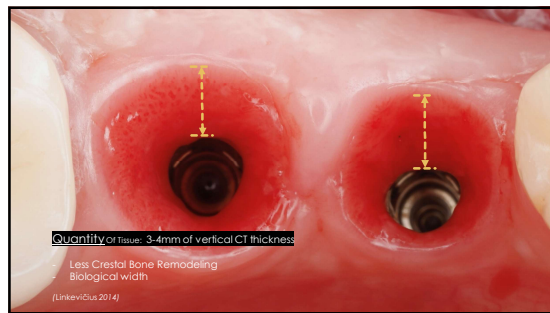
30



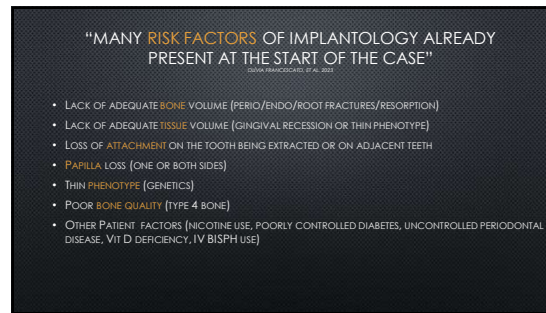
34



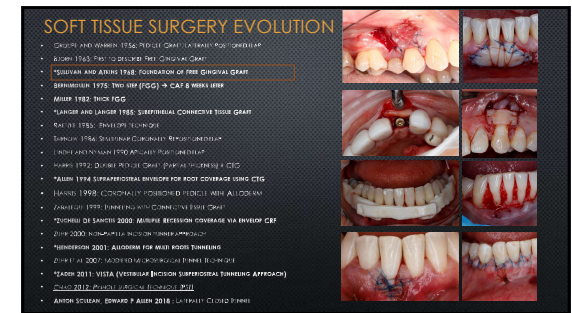45



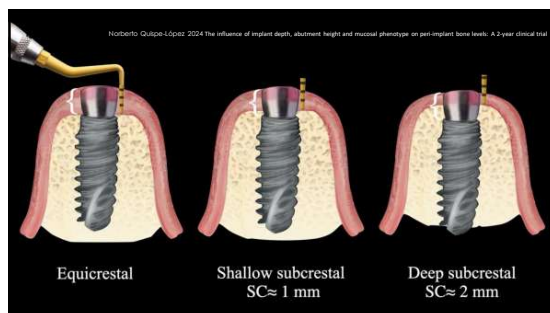
32



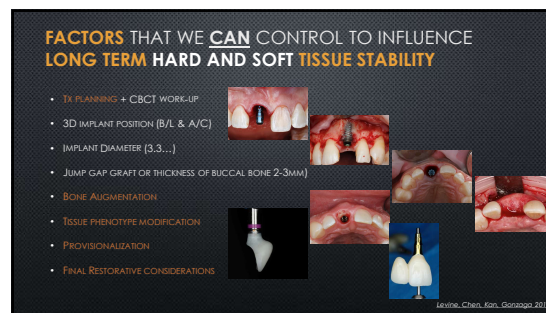
38



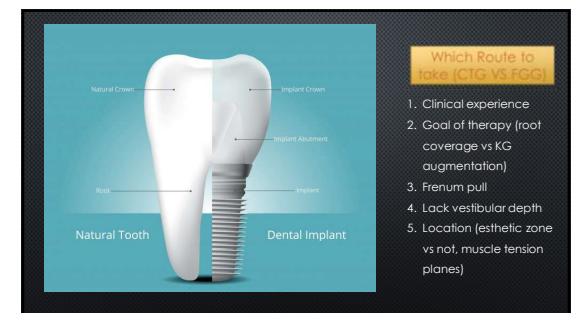46




33



39



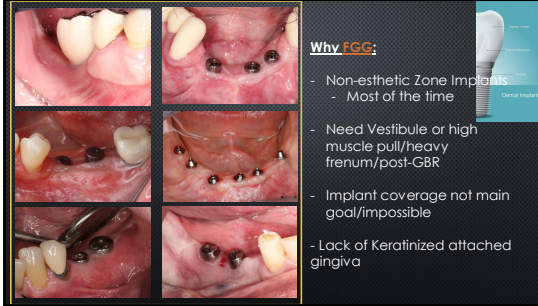
47



**Why CTG:**

- Esthetic Zone
- Decent Vestibule or lack of muscle pull
- Root coverage is the main goal or possible/predictable

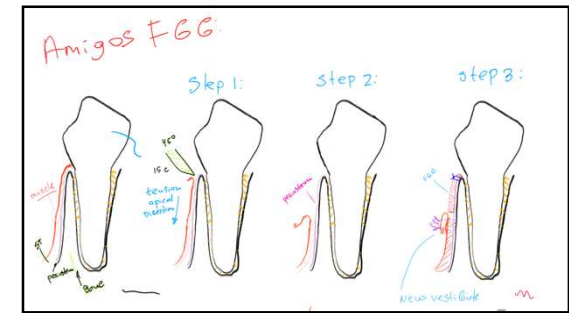
48



**Why FGG:**

- Non-esthetic Zone Implants - Most of the time
- Need Vestibule or high muscle pull/heavy frenum/post-GBR
- Implant coverage not main goal/impossible
- Lack of Keratinized attached gingiva

51



54



**Why FGG:**

- Non-esthetic zone (\*\*\*)
- Need Vestibule or high muscle pull/heavy frenum
- RC not possible
- Need KG

49

**FREE GINGIVAL GRAFT (FGG)!!!**

- FIRST DESCRIBED IN LITERATURE BY **BLOOM 1963** AND REVIEWED **SULLIVAN AND ATKINS IN 1968**
- DONOR TISSUE IS **EPITHELIAL TISSUE** (VS CONNECTIVE TISSUE) OR SURFACE OF THE PALATE
- MOST PREDICTABLE PROCEDURE IF **KERATINIZED GINGIVA** IS DESIRED
- NOT AS ESTHETIC AS CT (BEEN CALLED TIRE PATCH)




- USUALLY NOT USED FOR ROOT COVERAGE (BUT CAN BE)
- KEY TO SUCCESS IS **IMMOBILIZATION**
- IT **CAN** BE THE MOST UNCOMFORTABLE PROCEDURE OF **ALL** SOFT TISSUE PROCEDURES WE DO!

52

**THICKNESS OF DONOR TISSUE**

Recommended Thickness is ~ 1.3mm (Sullivan and Atkins)



59




**Why CTG:**

- Esthetic Zone Implants
- Need Contour Change or Increase in volume/height of tissue
- papilla recon
- Implant coverage is the main goal/and is possible
- Vertical Height Gain

50

**HEALING OF THE FREE GINGIVAL GRAFT**

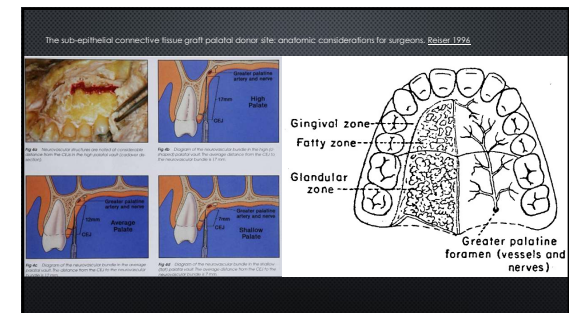
Sullivan and Atkins in 1968 described initial stages of Graft Maturation after a Free Autogenous gingival graft: Stages of a Graft "Take"



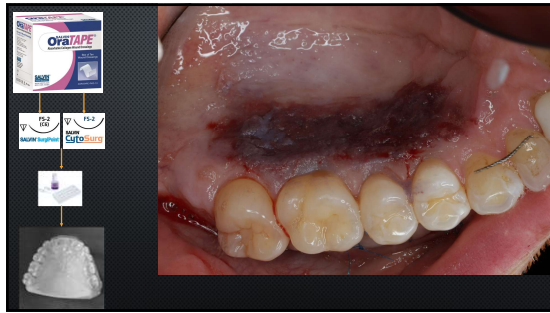- 1. Plasmatic circulation:** the graft is solely dependent upon diffusion from its host bed and occurs most efficiently through the fibrin clot (0-24 hours)
- 2. Vascularization (24-48 hours):** re-establishment of vascularization occurs first by capillary proliferation at the end of the first day. By the 2nd or 3rd day some capillaries have extended into the graft. Adequate blood supply appeared around the 8th day.
- 3. Organic union:** organic tissue union develops between the graft and bed, beginning on the 4/5th day and is complete by the 10th day (also lends to secondary contraction of the graft)

1 week post op

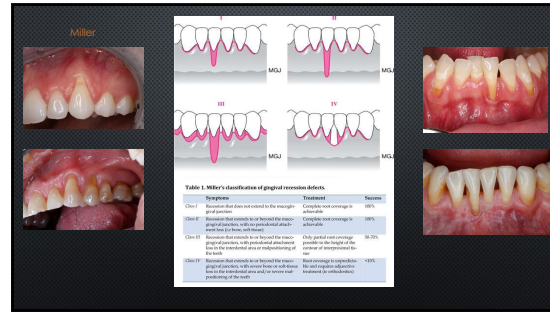
53



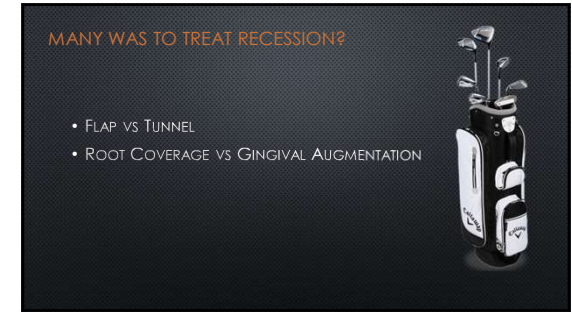61



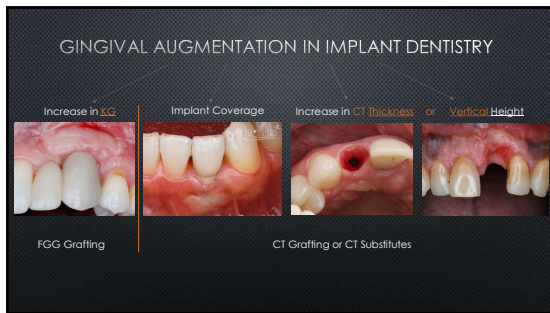
70



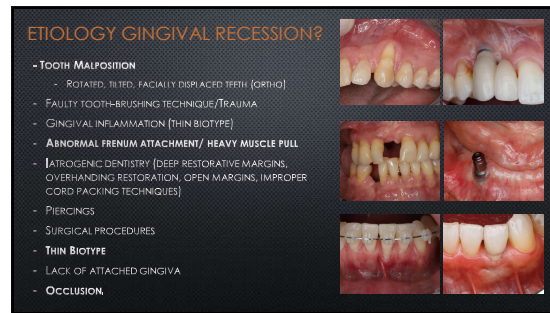
88



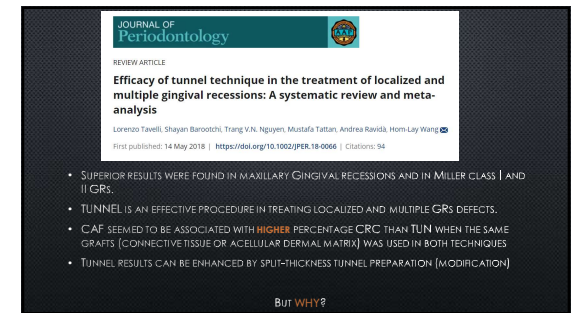91



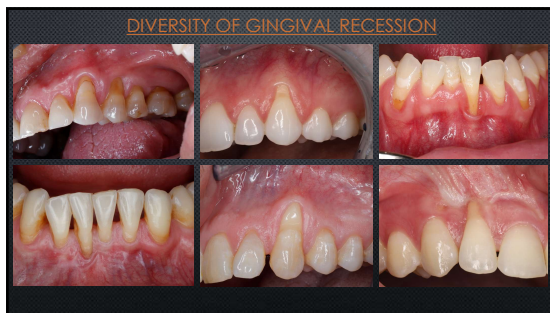86



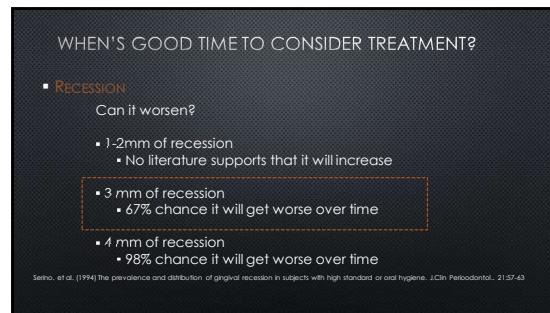
89



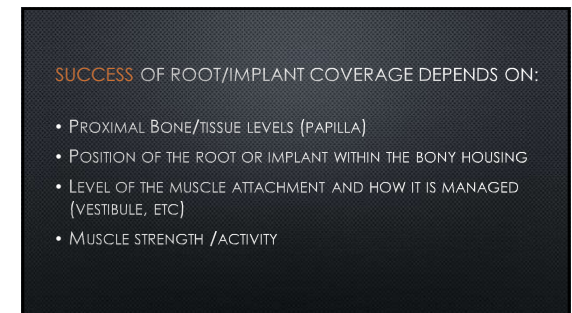
92



87




90



93


### MANY WAYS TO ROOT OR IMPLANT COVERAGE?

- TUNNEL (P ALLEN)
- VISTA (ZADEH)
- LATERALLY CLOSED TUNNEL (ALLEN/SCULLEAN)
- ZUCHELLI FLAP
- PEDICLES (VIP)
- CTG (AUTOGENOUS); FREE OR VIP
- FGG
- ALLOGRAFT
- XENOGRAFT (OSSIX VOLUMAX, FIBROGIDE)



94

### SINGLE INCISION TECHNIQUE (SECTG)



Step 1: shallow, define depth of epithelial split

Step 2: extend split M/D and extend apically in one plane


Step 3: Place M/D → apical → coronal cuts

105

Case Reports | Int J Periodontics Restorative Dent. 2018 Jul;Aug;38(4):479-487. doi: 10.11607/prd.3680.

### The Laterally Closed Tunnel for the Treatment of Deep Isolated Mandibular Recessions: Surgical Technique and a Report of 24 Cases

Anton Sculean, Edward P Allen  
PMID: 29889911 DOI: 10.11607/prd.3680



119

### SOURCES OF DONOR TISSUE

- AUTOGENOUS**
  - SECTG
  - D-FGG "the gold standard"
  - TUBEROCTY CTG
  - VIP-CTG
- SUBSTITUTES**
  - SOFT TISSUE ALLOGRAFT (I.E. SALVIN DERMIS ETC)
  - XENOGRAFT (I.E. OSSIX VOLUMAX, GESTICHT FIBROGUIDE)

CHAMBERS AND TAMURA. J PERIODONTOL 2015;86(suppl 1):SCTG-MANIP. TECHNIQUES PROVIDE THE BEST OUTCOME FOR MEAN AND COMPLETE ROOT COVERAGE, AS WELL AS AN INCREASE IN KT.

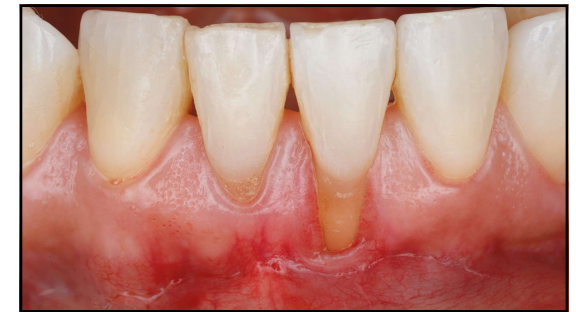


103

### TWO WAYS TO CREATE D-FGG



- INTRAOALLY WITH BURS
- EXTRAORALLY WITH BLADE

108



120

### Comparison between Subepithelial Connective Tissue Graft and De-epithelialized Gingival Graft: A systematic review and a meta-analysis

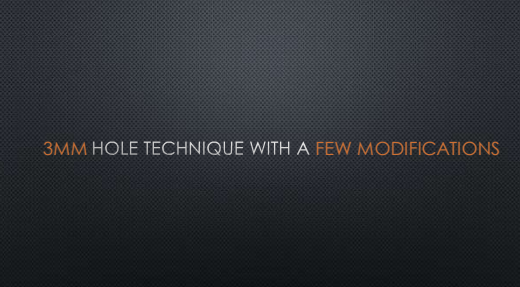
TAVELLI ET AL., 2019

- DGGG SHOWED OVER ALL BETTER RESULTS**
  - MRC, RESSION REDUCTION, KG GAIN, PO CHANGE, CAL GAIN

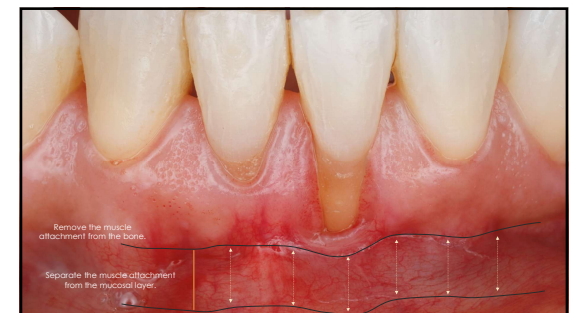
Department of Periodontics & Oral Medicine, University of Michigan School of Dentistry, Ann Arbor, MI, USA; Department of Clinical Sciences, University of California, San Francisco School of Dentistry, San Francisco, CA, USA; Department of Periodontics, University of Oklahoma Health Sciences Center, Oklahoma City, OK, USA

104

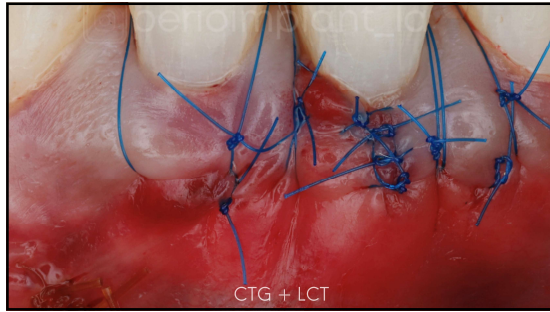### 3MM HOLE TECHNIQUE WITH A FEW MODIFICATIONS



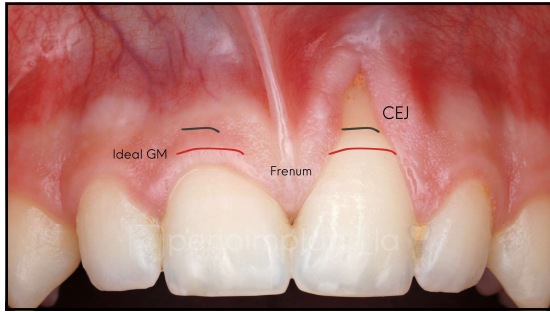
118



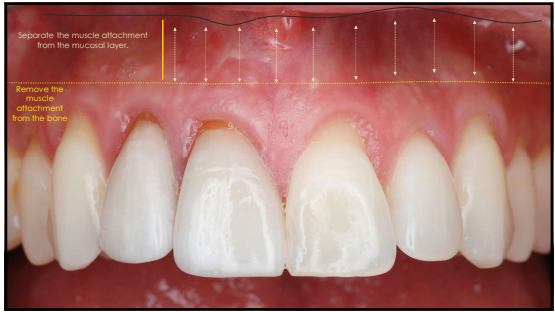121



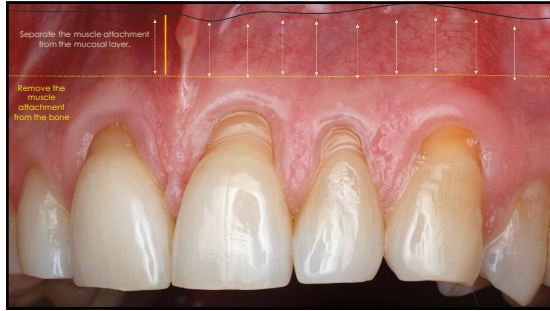
123



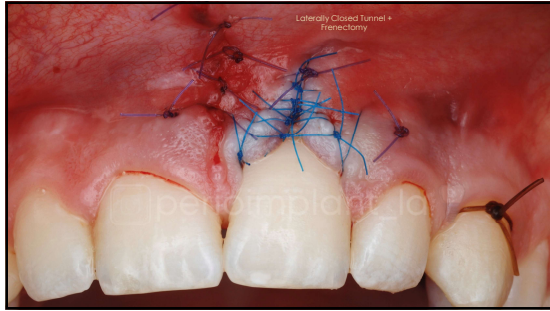
131



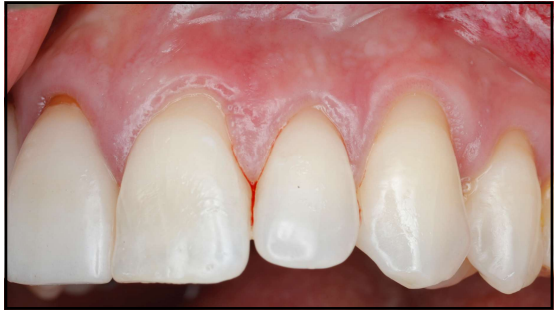137



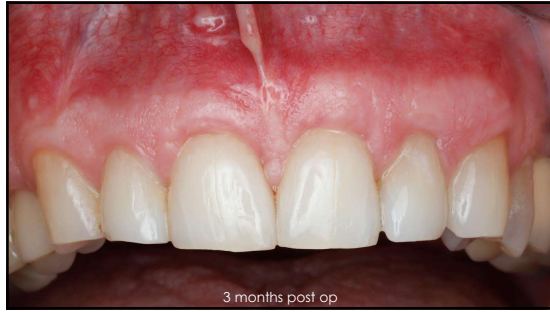126



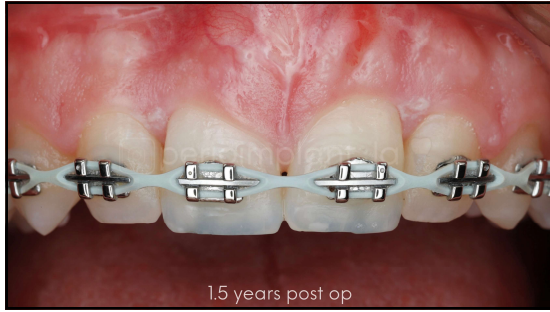133



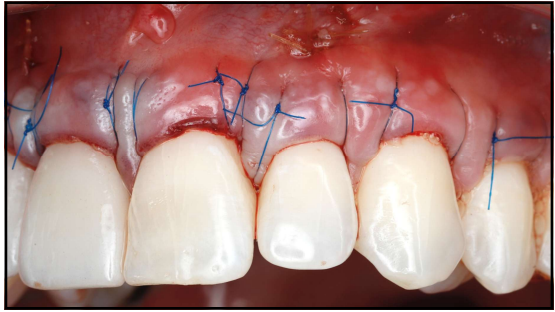
139



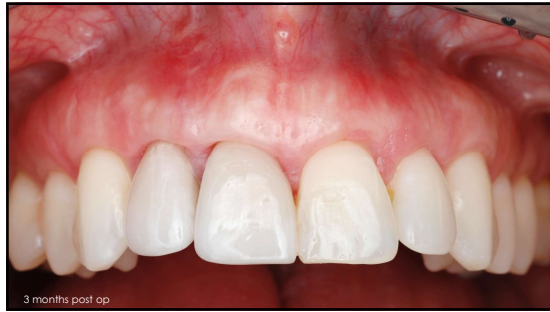130



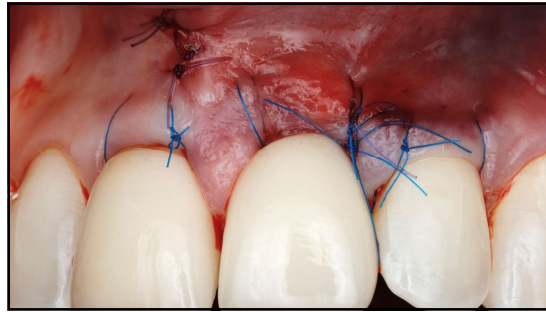
136



143



144



149

### Aesthetic Zone Temporization Protocols

Optimize the Hard and Soft Tissue Outcomes for Long-term Success

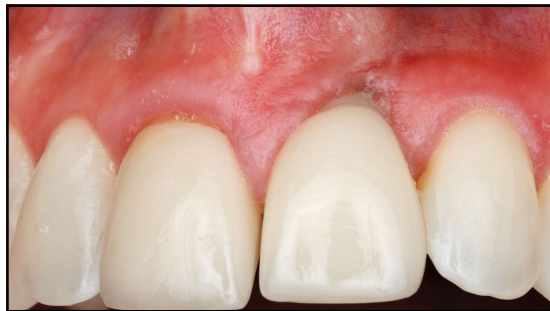**IMMEDIATE IMPLANT PROTOCOLS**

- CUSTOM HEALING ABUTMENT
- IMMEDIATE TEMP

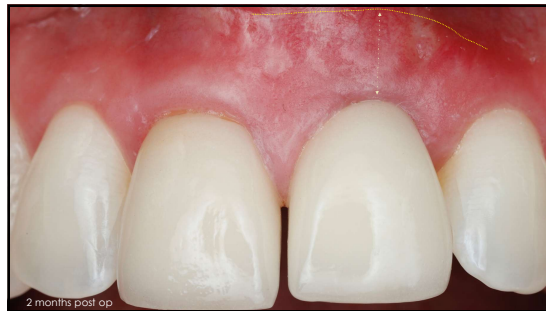**DELAYED IMPLANT PROTOCOLS**

- NARROWEST POSSIBLE HA THEN TEMP IN AT LEAST 6-8 WEEKS
- PRIMARY CLOSURE (IF ADVANCED BONE/TISSUE GRAFTING)
- IF BONE ONLY = OPEN FULL FLAP TO MANAGE ST
- IF TISSUE ONLY = BIOPSY PUNCH EXPOSURE AND TEMP

155



146



150

### Should I CTG in Aesthetic Zone vs NOT?

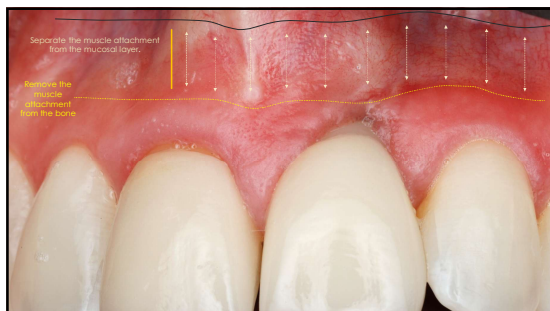SEYSSENS L, DE LAT L, COSYN J. IMMEDIATE IMPLANT PLACEMENT WITH OR WITHOUT CONNECTIVE TISSUE GRAFT: A SYSTEMATIC REVIEW AND META-ANALYSIS. J Clin Periodontol. 2021

- CONNECTIVE TISSUE GRAFTS (CTG) AID IN MAINTAINING MID-FACIAL SOFT TISSUE STABILITY AFTER IMMEDIATE IMPLANT PLACEMENT (IIP). THIS CTG IMPROVES BY CONNECTING WITH THE EXISTING BONE, THERE IS A REDUCED RISK OF MID-FACIAL RECESION IN THE AESTHETIC ZONE (THIN GINGIVAL BIOTYPE, <0.5 MM BUCCAL BONE THICKNESS).

**BUCCAL BONE THICKNESS**

- ZHANG ET AL. (2016) NOTED MEASUREMENTS RANGING FROM 0.56 TO 0.65 MM IN THE CREST AND MIDDLE BUCCAL AREAS.
- D'HEMES (2021) STATED THAT IN MORE THAN 60% OF CASES, THE BUCCAL BONE THICKNESS (BBT) AT THE ALVEOLAR CREST IS THINER 1 MM IN BOTH THE MAXILLARY AND MANDIBULAR ANTERIOR REGIONS.
- A SYSTEMATIC REVIEW BY TODOROVIC (2023) INDICATED THAT BUCCAL BONE THICKNESS RARELY EXCEEDED 0.5 MM.

156



147

### Aesthetic Zone Temporization Protocols

Optimize the Hard and Soft Tissue Outcomes for Long-term Success

Immediate implant protocols:

- CUSTOM HEALING ABUTMENT
- IMMEDIATE TEMP

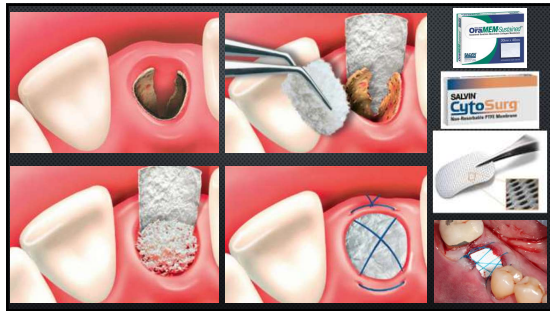
154

### THE DUAL-ZONE THERAPEUTIC CONCEPT

S. Chiu, Maurice A. Salamao, D. Tarnow 2012

157





206

### 4 PASS PRINCIPLES FOR GUIDED BONE REGENERATION: (HL WANG 2006)

- (P) : **PRIMARY WOUND CLOSURE** TO ENSURE UNDISTURBED AND UNINTERRUPTED WOUND HEALING
- (A) : **ANGIOGENESIS** TO PROVIDE NECESSARY BLOOD SUPPLY AND UNDIFFERENTIATED MESENCHYMAL CELLS
- (S) : **SPACE MAINTENANCE** (CREATION TO FACILITATE ADEQUATE SPACE FOR BONE INGROWTH
- (S) : **STABILITY** OF WOUND AND IMPLANT TO INDUCE BLOOD CLOT FORMATION AND UNEVENTFUL HEALING EVENTS

215

### Vertical Bone Grafting and Periosteal Vertical Mattress Suture for the Fixation of Resorbable Membrane and Stabilization of Particulate Grafts in Horizontal Guided Bone Regeneration to Achieve More Predictable Results: A Technical Report

**Can do external knots or internal knots**

230

### TX PLAN OPTIONS FOR MANAGEMENT OF BONE DEFICIENCIES

**BONE GRAFTING WITH MEMBRANES**

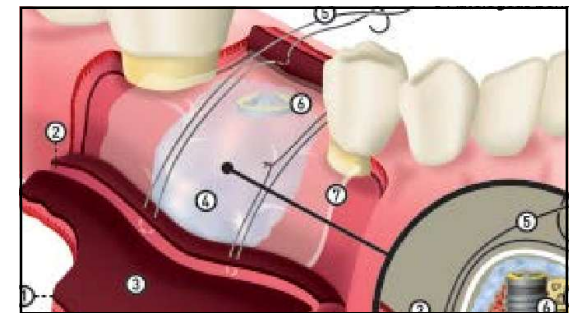
- ALLOGRAFT PARTICULATE OR BLOCK (MINERALIZED VS DEMINERALIZED, CORTICAL VS CANCELLOUS)
- AUTOGENOUS PARTICULATE OR BLOCK/PLATE (PIKOS THICK BLOCK VS KHOURY THIN BLOCKS)
- XENOGRAFT + AUTOGRAFT (URBANS 2011) **SAUSAGE TECHNIQUE**
- XENOGRAFT OVER AUTOGRAFT (URBAN/HL WANG 2013) **SANDWICH TECHNIQUE**
- **OSSIODENSIFICATION** (HUWALS, 2015)
- **BIOLOGICS** (PRF, Gem21)

213

### BONE GRAFT STABILIZATION TECHNIQUES:

- **SAUSAGE TECHNIQUE USING BONE TACKS** (URBAN 2011)
- **Periosteal Vertical Mattress Suture** (Urban, HL Wang 2016)

216



231

.....principle of GBR using **barrier membranes**, either resorbable, to exclude certain cell types such as rapidly proliferating epithelium and connective tissue, thus promoting the growth of slower-growing cells capable of forming bone.

GBR is often combined with bone grafting procedures

\* Retzepl M, Donos N 2010

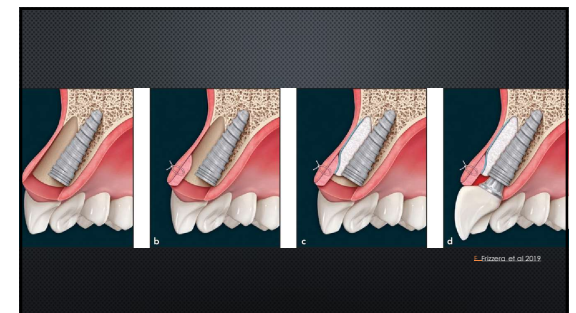
214

### TYPES OF FLAPS

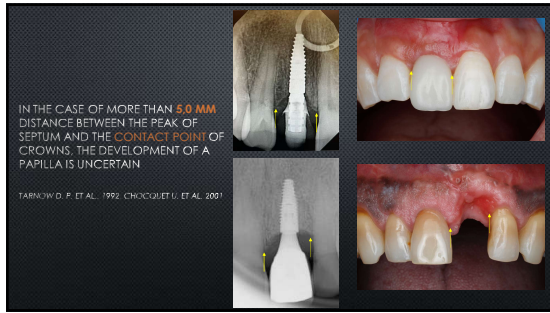- ENVELOPE (A)
- TRAPEZOIDAL (B)
  - PAPILLA SPARING
  - NON PAPILLA SPARING
- TRIANGULAR (C)
- SEMILINAR (D)

**Vertical incision: ZPLS**  
 • Very base of the vertical can be curved toward the flap for increased flap advancement  
 • Coronal position of vertical should be close to perpendicular to the angle of the tooth

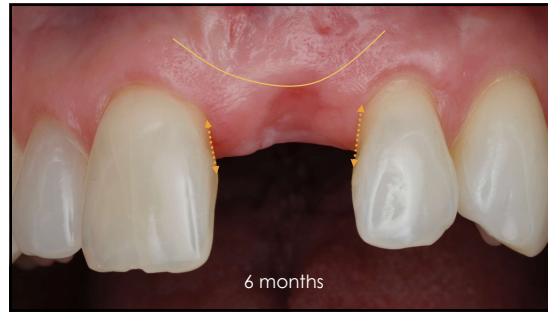223



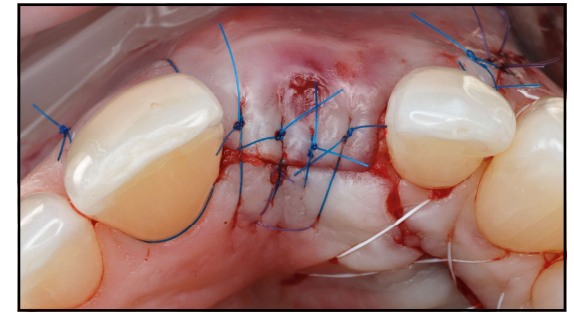
268



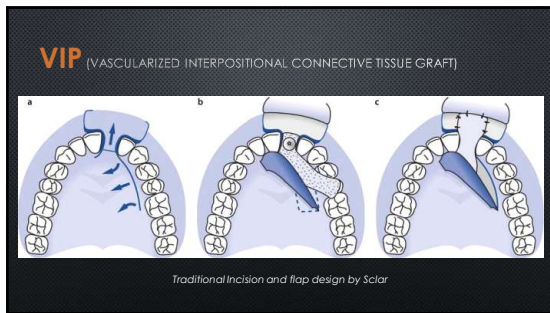
281



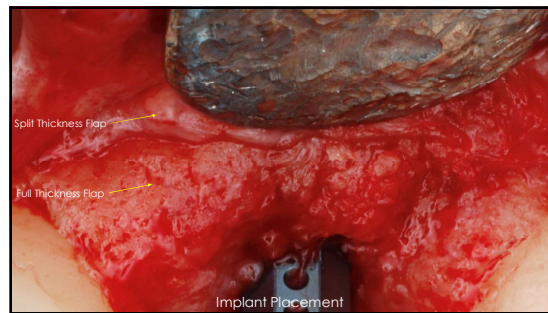
294



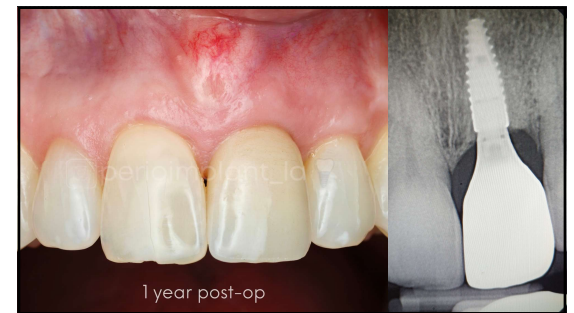300



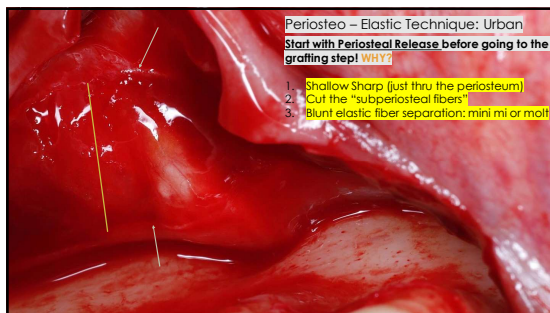
283



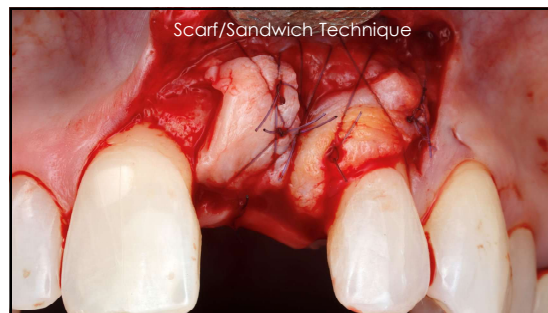
296



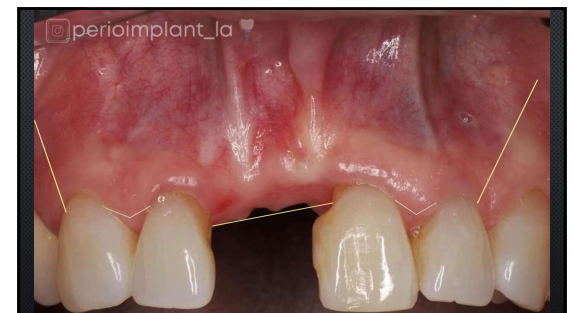310



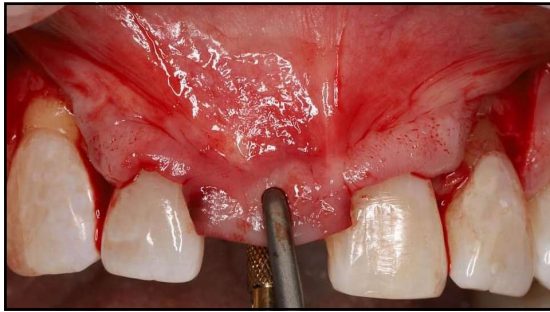
289



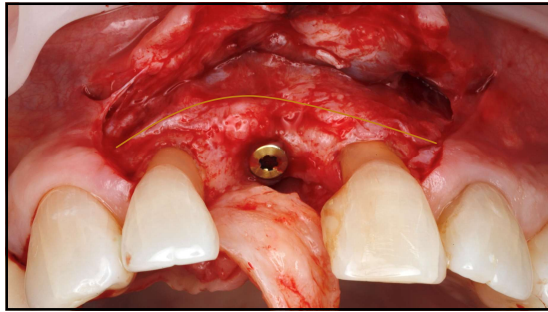
298



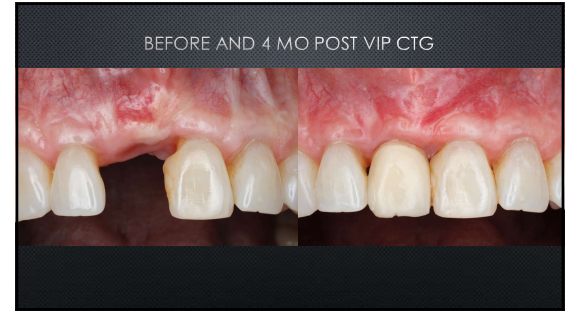311



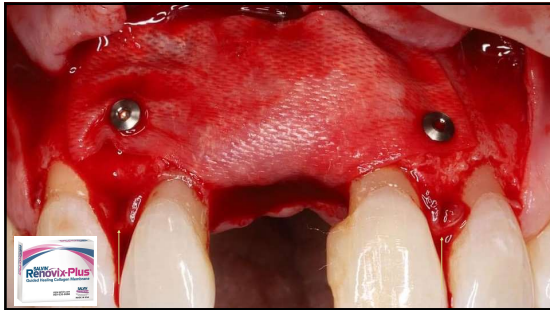
313



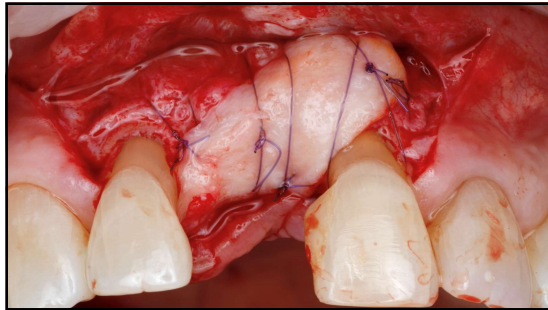
319



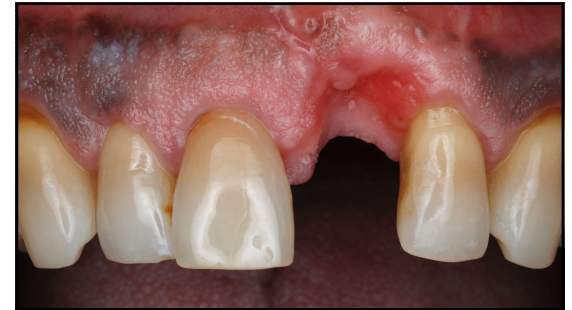332



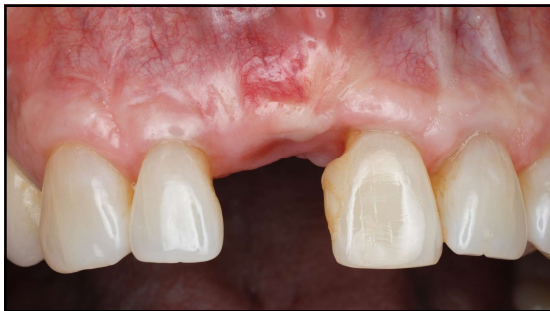314



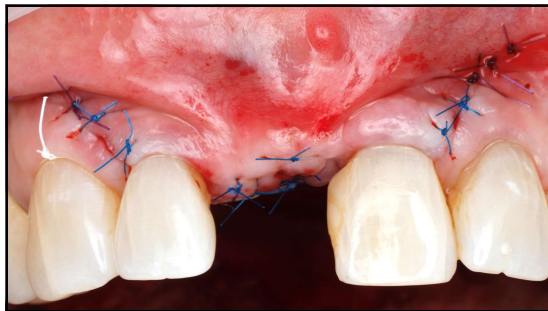
322



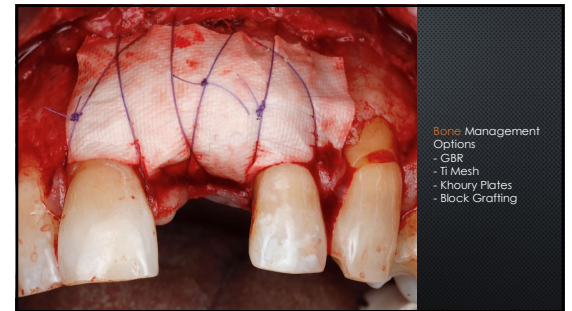
366



318

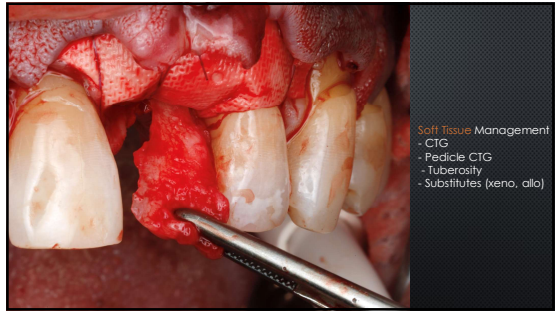


323

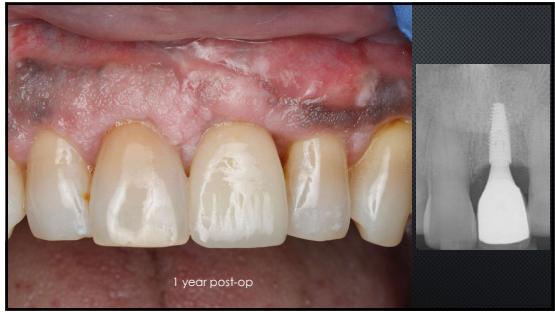

367

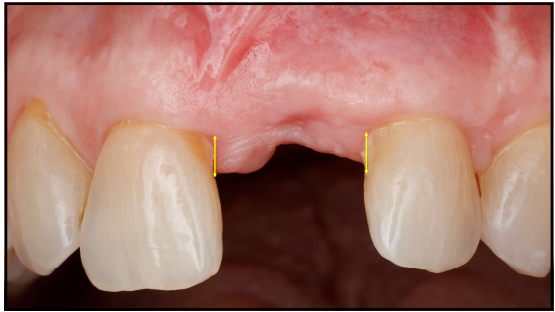
- Bone Management Options
- GBR
  - Ti Mesh
  - Khoury Plates
  - Block Grafting



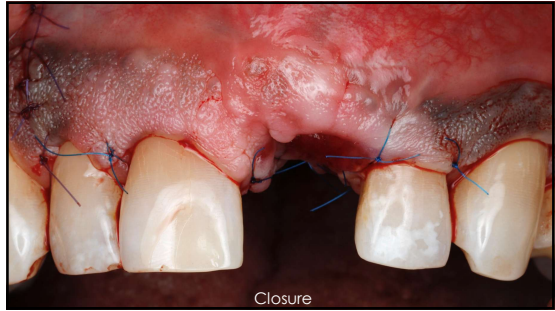
368



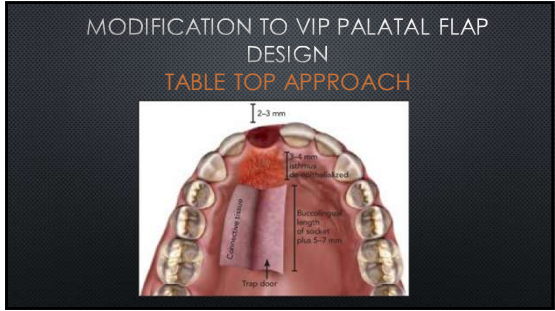
392



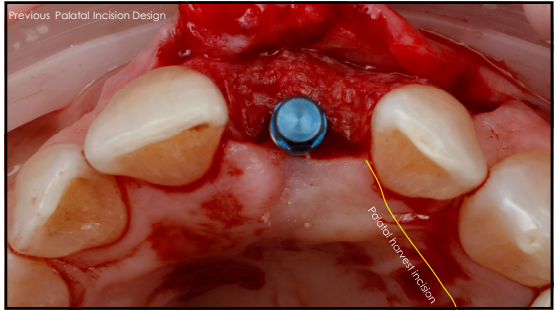
425



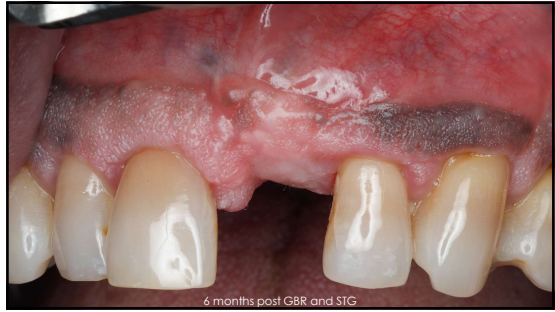369



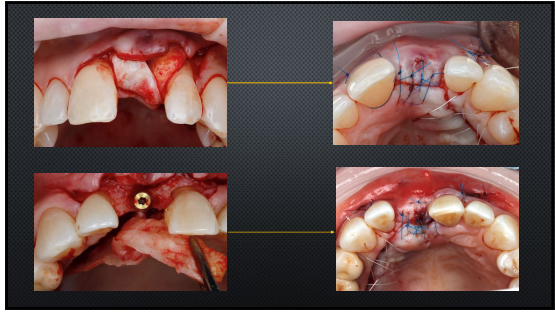
423



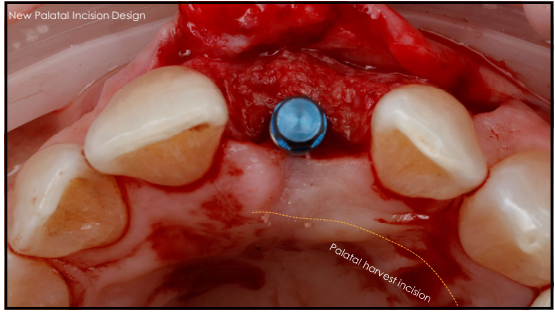
426



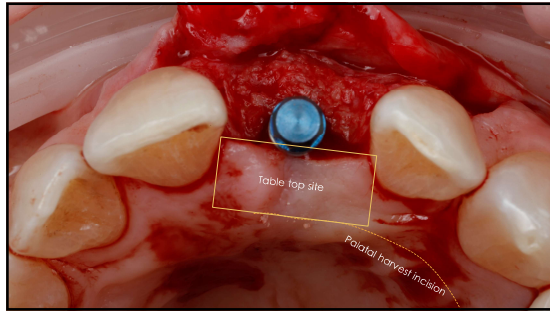
370



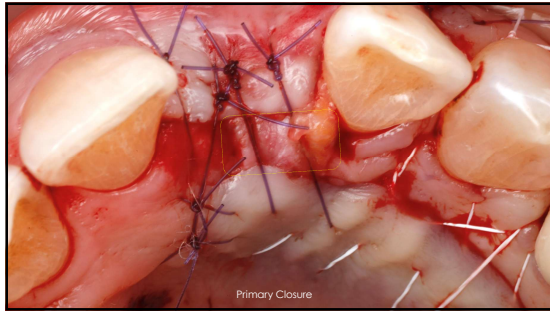
424



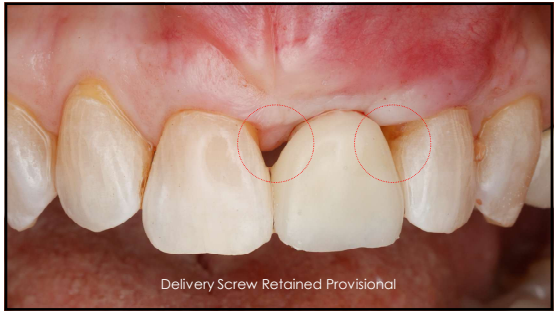
427



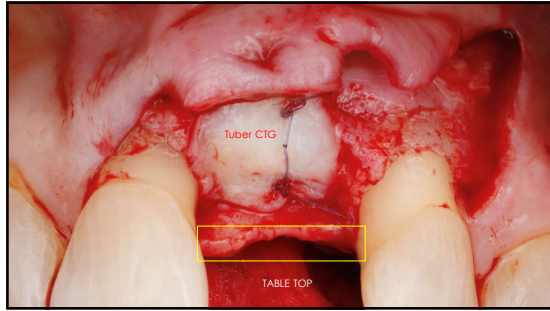
428



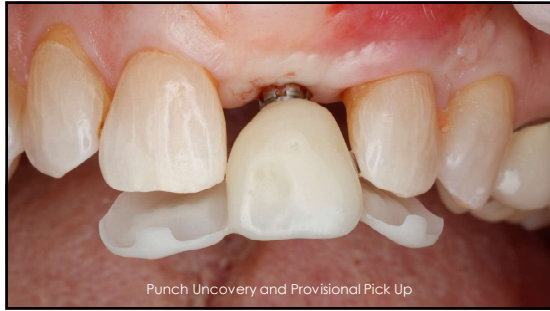431



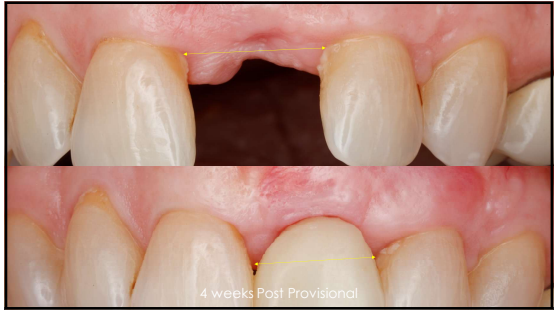439



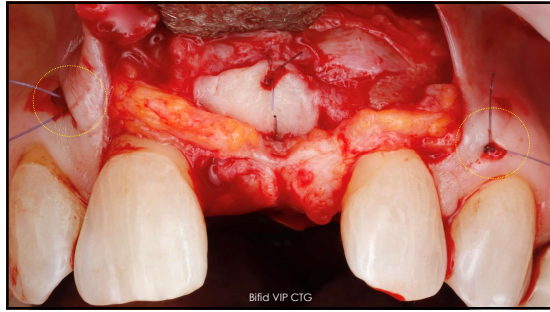
429



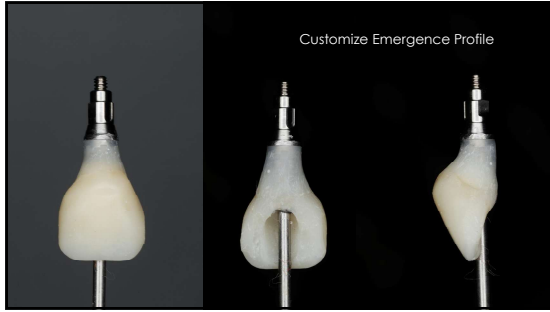437




441



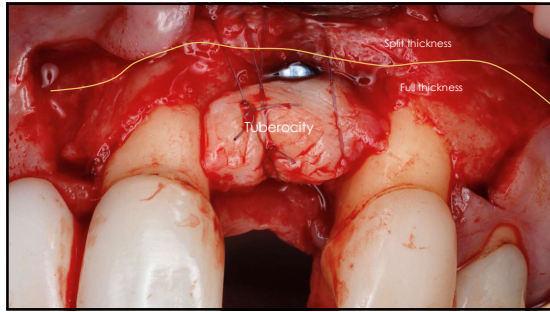
430



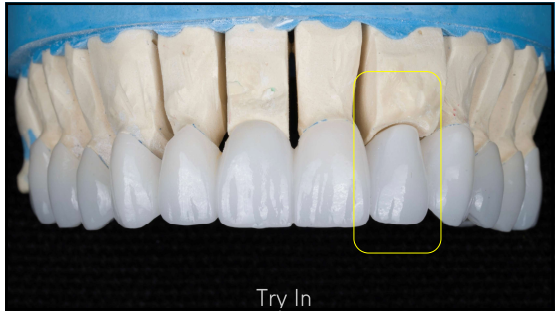
438



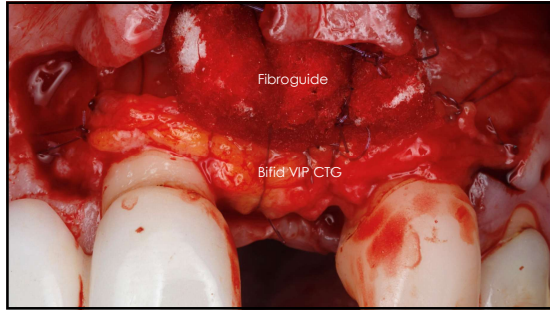
443



453



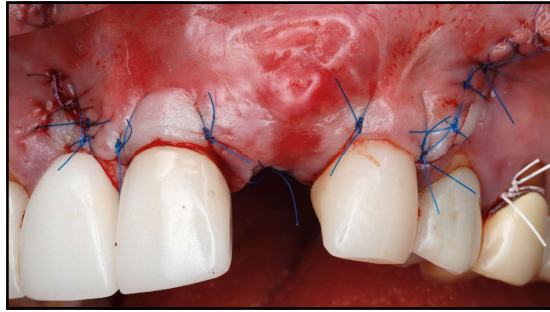
459



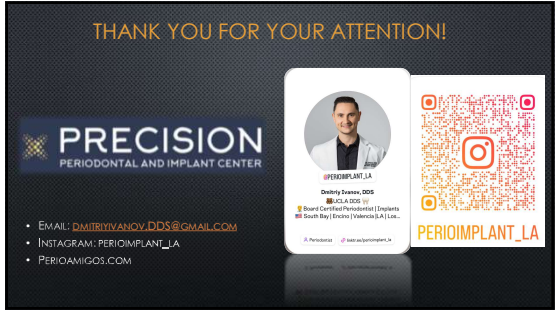
454



462



455



463